# Common soft tissue injuries in high-level sport horses

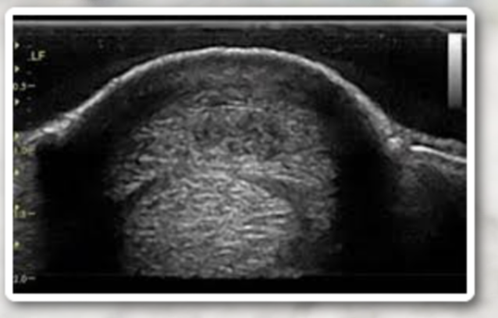

Image 1 (TOP) : An ultrasound image of the flexor tendons of a forelimb. A grade 4 (severe damage) lesion of the superficial digital flexor tendon. This lesion takes up approximately 50% of the maximal cross sectional area of the tendon.

Image 2 (BOTTOM): A typical appearance of superficial tendonitis. "bowed tendon".

**The following article will address a few of the more common soft tissue injuries and problems seen in performance horses.**

**A soft tissue injury is one involving skin, muscle, tendons, ligaments and or nerves. Most of these injuries (but not all) will result in the horse becoming lame (see previous issue of "determining if your horse is lame" in Hoofbeats), but will all result in decreased performance in the equine athlete.**

## Tendon Injuries

### The superficial digital flexor tendon (SDFT)

Over-strain injury of the superficial digital flexor (SDF) tendon is common in performance horses. This tendon runs from the back of the knee/hock down to the level of the pastern.
This type of injury is also known as tendonitis or a "bowed tendon" (see image 1 and 2). This damage occurs either due to chronic, low grade tearing of the tendon during fast work or less commonly due to a one-off traumatic injury. It should be noted that these horses are typically NOT lame but are painful on palpation of the tendon that is swollen and hot.

These SDFT injuries are slow to heal, with anywhere from 20-80% of affected horses returning to future competition. Such a variance in outcome is due to the different severity of injuries combined with treatments of the horse.

Treatments have previously included firing, blistering, tendon splitting, implantation of carbon fibres; and intra-lesional injection of, variously, corticosteroids, BAPTEN, polysuphated glycosaminoglycans, hyaluronic acid, and growth hormone. The range and variety of treatments for the condition attest to the difficulty in successfully rehabilitating affected animals.
What treatment a horse requires really depends on the type and severity of injury. No matter what, a graded training program (see attachment) back-to-work is essential for a successful outcome.

Recent research has turned the spotlight towards the use of mesenchymal stem cells, PRP (platelet rich plasma) or bone marrow aspirate. These cells are the natural units of adult tissue regeneration (as opposed to simply repairing or replacing with scar tissue). Use of one of the above treatments would be considered gold standard for management of this type of injury.

# Windgalls

Effusion of the flexor tendon sheath.
"Windgalls" are swellings of the digital flexor tendon sheath (which holds the tendons and the suspensory ligament in place) of the distal limbs. This flexor tendon sheath is normally filled with fluid which helps the tendons slide along the back of the fetlock joint. "Windgalls" occur when this tendon sheath fills with an excessive amount of fluid. These swellings are usually similar in size between pairs of limbs, and if the horse is not showing any signs of lameness is usually no cause for concern. Many apparently normal horses in full work have slight "windgalls", especially in the hind limbs. The amount of swelling may vary according to the environmental temperature, being less obvious in cold weather and frequently more filled in hot weather. If the swelling is on only one limb and your horse is lame then it may be cause for concern. Typically injuries that result in pathological "windgalls" include various low tendon injuries and annular ligament damage. Occasionally this tendon sheath can become infected from a laceration or wound. If any of the above has occurred your vet may perform an ultrasound exam of the tendons to check to see if they are affected. Sometimes a sample of the fluid within this sheath may be required.

The degree of swelling may also be influenced by exercise. Work often results in some reduction in swelling, whereas stable rest may result in accumulation of fluid and greater swelling. The size of the windgalls can be controlled by the application of stable bandages. These should be applied if they are unsightly and the horse is boxed overnight. Various corticosteroids and other medications can be injected into the tendon sheath to decrease the amount of swelling; however this response is usually only transient and often required repeated long-term injections.

# Suspensory Ligament

Injury of the interosseous muscle, commonly known as suspensory ligament, is an important cause of lameness in athletic horses. The suspensory ligament is an important piece of anatomy that runs down the back of both the fore and hind limbs. It originates from both the back of the carpus and hock and attaches to the fetlock joint. This ligament can be divided into three separate regions, which are subject to injury: the proximal part, the body, and the branches. Injurys to all these areas occur and are all treated and managed very differently.

## Proximal Suspensory Desmitis (PSD):

This injury occurs in the suspensory ligament attachment at the proximal MC or MT3 just below the carpus or hock. Desmitis means "inflammation of a ligament – which results in pain. Horses are typically lame bilaterally, with one leg being more pronounced than the other. It should also be noted that PSD in the hind limbs is more common in straight-hocked horses. Sometimes a pain response can be trigger if pressure is applied to the proximal suspensory attachment area.

Treatments for PSD include rest, shockwave therapy (see image 4), localized injections and neurectomy and fasciotomy surgeries. Horses with hind limb PSD respond poorly to rest while other therapies have mixed results. Horses that fail to respond to rest and other types of medical therapies are candidates for the surgery. The surgery can be performed on both forelimb and hind limb PSD injuries.




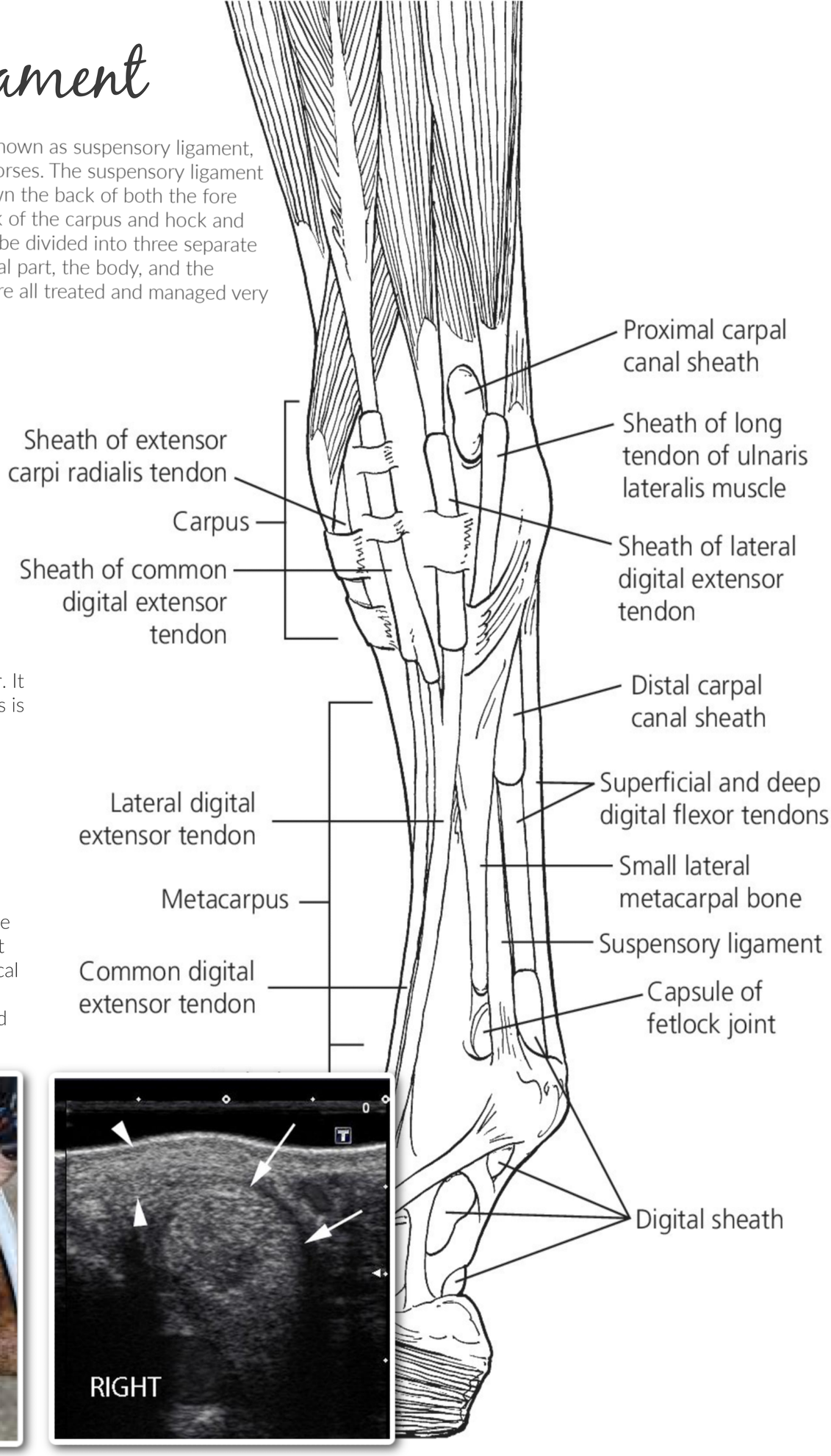


# Suspensory ligament body and branch injuries:

These lesions are tears similar to that seen in superficial digital flexor tendonitis. Tearing of ligament fibers typically leave a black hole in the ligament (see image 7).

Direct PRP (platelet rich plasma), bone marrow and stem cell injections into the lesion have been advocated to speed healing. This is a very similar process to that of injection into a SDFT injury. Good-excellent results have been seen when using either PRP or bone marrow injections when combined with a graded rehabilitation program.



Image 7: An ultrasound image of a damaged suspensory ligament in a forelimb. This "hole" is in the mid-body of a suspensory ligament.

Image 8: An ultrasound guided injection of an SDFT lesion in a forelimb. PRP was injected into a large hole within the SDFT.

# Sacro-iliac disease

Sacro-iliac disease is seen occasionally in performance horses, especially with jumping disciplines. Muscular pain in this area usually occurs secondarily to a lameness issue future down the hind limb but can also be from a primary disease process to the area (e.g. arthritis or ligament strain). Injuries to this area are diagnosed using a combination of clinical examination, nerve blocks and medical imaging techniques (see previous article).

Treatment of sacro-iliac issues includes massage techniques, acupuncture, Shockwave therapy, NSAIDs (e.g. "Bute") medication and direct injections into the area (see image 7). All of these treatment techniques allow pain relief in order to allow the horse to start using the fine motor muscles once again around the area. This therefore minimizes instability of the area and reduces pain.

Red light therapy, magnets, crystals and other alternative therapies have been used on all of the above injuries. None of these therapies have been proven to improve healing during scientific trials, however no harm can usually be done. Some individual horse may actually respond well to alternative therapies, however all treatment should be used under the guidance of a professional.

In conclusion there are many soft tissue injuries that horses can acquire. For best results early diagnosis combined with the correct therapy and rehabilitation program should be performed in order to get the best long-term outcome for your animal.

Image 9: An ultrasound guided sacroiliac injection. This injection will allow medications (cortisone) to be deposited deep into the muscle just adjacent to the sacroiliac joint.

# Example of Post-PRP or stem cell Rehabilitation Program:

**Platelet rich plasma, bone marrow or stem cells are injected into a core lesion. Following this a controlled rehabilitation program is undertaken.**

**Week 1:** Stall rest.Bandage the limb for the 1st 48 hours.Phenylbutazone (Bute) – 5mls orally once daily for 6 days. 25mls penicillin (PPG), into the muscle, twice daily for 2 days.

**Week 2-4:** Stall rest/small yard with 5 minutes hand walking (very slow) twice daily.

**Week 4 -6:** Horse can be placed into a larger yard. Walking can be now increased to 10 minutes walking (slow) twice daily.

**Week 6-8:** Increase walking to 15 minutes twice daily.

**Week 8 -12:** 20 minutes walking twice daily**.**

**3rd month after injection:** Tendon/ligament scan to monitor progress of healing. walking 30 minutes twice daily if tendon is healing adequately.

**4th month after injection:** Walking 40 minutes twice daily.

**5th month after injection:** Tendon/ligament scan to monitor progress of healing.
Horse can be placed into a paddock. Walking under saddle can now begin. Introducing 1 or 2 trotting periods weekly

**6th month after injection:** Add periods of jog every week

**7th month after injection:** Increase periods of jog

**8th month after injection:** Tendon/ligament scan to monitor progress of healing. 45 minutes exercise daily with slow canter (pending ultrasound scan), gradually increasing in amount.

**9th month after injection:** Start work as usual